



AMELIORATIVE EFFECT OF *COCOS NUCIFERA* (COCONUT) WATER ON GENTAMYCIN INDUCED RENAL TOXICITY IN ADULT WISTAR RAT

Ehimigbai, Agbonluai Richard O.^{1*}, Anunobi, Arinze Albert²

¹Lecturer, Department Of Anatomy, Faculty of Basic Medical Science, College of Medical Science, University of Benin, Benin City, Edo State, Nigeria

²Research Assistant, Department Of Anatomy, Faculty of Basic Medical Science, College of Medical Science, University of Benin, Benin City, Edo State, Nigeria

*Corresponding Author Email: ehirichard22@yahoo.com

DOI: 10.7897/2277-4572.04337

Received on: 05/04/15 Revised on: 18/05/15 Accepted on: 24/05/15

ABSTRACT

The ameliorative potential of *Cocos nucifera* water in gentamycin induced kidney toxicity was evaluated using adult wistar rats. Twenty-four (24) adult wistar rats weighing between 190g to 240g were assigned to 4 groups of 6 rats each and the gentamycin were administered intraperitoneally while the *Cocos nucifera* water was given via orogastric tube for 24 consecutive days. Group A rats representing the control were fed normal diet and water ad libitums; while Group B were treated with 1ml of *Cocos nucifera* water only, Group C were treated with 100mg / kg gentamycin only, and Group D were treated with 1ml *Cocos nucifera* water and 100 mg / kg gentamycin respectively. Biochemically, the result showed that Oral administration of 100mg / kg gentamycin revealed marked kidney toxicity as showed by elevation in the activity of the serum urea, creatinine, superoxide dismutase and catalase along with decreased level of malonyl dehydrogenase. The control group, the *Cocos nucifera* water only group and the co- administered group of both *Cocos nucifera* water and gentamycin showed normal biochemical value of serum urea, creatinine, superoxide dismutase catalase and malonyl dehydrogenase. Histologically, the gentamycin only group showed focal areas of tubular epithelial cloudy swelling and mild interstitial congestion. While the co- administered group of both *Cocos nucifera* water and gentamycin showed normal cytoarchitectural structure of the kidney. In conclusion, these results as evidenced by histological and biochemical parameters suggested that *Cocos nucifera* water possessed ameliorative potential on gentamycin induced kidney toxicity.

Keywords: *Cocos nucifera* water, Gentamycin, Kidney, Catalase, Urea, Creatinine and toxicity.

INTRODUCTION

Gentamycin is among the antibiotics that are very potent in the treatment of microorganisms that are gram negative. This drug like other aminoglycosides causes nephrotoxicity by inhibiting protein synthesis in kidney cells. This mechanism particularly causes necrosis of renal cells in the proximal tubule, leading to acute tubular necrosis which can result into acute renal failure.¹

Cocos nucifera is naturally a tall palm tree that is cultivated in the tropical region. Its Fruits are arranged in cluster in various level of development.²

The use of *Cocos nucifera* water to neutralize poisons is a popular practice in Africa. It has quite a lot been used as an acute therapy for effects of drug over dosage.³ Studies have revealed that *Cocos nucifera* water have organic compound that hold a strong growth promoting abilities which is been used as a therapy in the treatment of kidney and urethral stones.⁴ It contains mainly fats, proteins, sodium, magnesium, potassium and calcium.^{5,6}

Furthermore, Aluisio et al. ⁷ stated that the fractions of *Cocos nucifera* water can act as a prospective natural antioxidant due to its free radical scavenging strength.

MATERIALS AND METHODS

Collection / Preparation

Thirty pieces of coconut which were stored in cold atmosphere were purchased from Ikhin market in Owan East Local government Area of Edo State, Nigeria. It was identified by a curator in the department of Pharmacognosy, University of Benin, Benin City.

The fibers covering the *Cocos nucifera* were removed before cracking it with the back of a knife. The liquid endosperm of the cracked *Cocos nucifera* which is the water is then poured inside a clean container. One *Cocos nucifera* is cracked per day for this experiment.

The gentamycin sulphate injection was manufactured by Yanzhou Xier Kangtai Phamia. Co. Limited Yanzhou, Shandong, China.

Experimental animals: Twenty four adult wistar rats with varying weight of 180- 200g were randomly assigned into four groups; control group A (n=6), treatment group; group B (n=6) and group C (n=6) and group D (n=6). The rats were obtained and maintained in the Animal House of the Department of Anatomy, School of Basic Medical Sciences, University of Benin, Benin city, Edo State, Nigeria. The wistar rats were kept in a ventilated cage for 2 weeks before the experiment for proper acclimatization. Food and clean water were given liberally. They were placed on standard livestock feed (vital growers feed).

The wistar rat experimental usage was in according to the National Institutes of Health Guide for the care and use of laboratory Animals (NIH, 2002 publication, No. 83-23), (Revised 1978).

Table 1: Schedule for Administration of Rifampicin and *Cocos nucifera* Water in Rats

Groups	Dose/kg body weight	No of Days/ Route
A Control group	Feed on normal rat chow and tap water ad libitum	24 days/orally
B Renoprotective group	1ml <i>Cocos nucifera</i> water ⁸	24 days/orally
C Renotoxic group	100mg / kg gentamycin ⁹	24days /intraperitoneally
D Combined group	1ml <i>Cocos nucifera</i> water plus 100mg / kg gentamycin	24 days/orally. 24 days / intraperitoneally.

The animals were anaesthetized using chloroform inhalation on the 25th days of experiment. A midline incision was made on the abdomen using a surgical blade and the kidneys were dissected out and fixed in 10% formal saline for histological analysis.

Histological Techniques

The laboratory chemicals used for the experiment were obtained from Patani chemicals limited Benin city, Edo State. The tissues were dehydrated in ascending grades of alcohol, cleared in xylene before embedded in paraffin wax. The tissue blocks were then sectioned at 5 micron per thickness by using a rotary microtome. The deparaffused tissue sections were stained with Haematoxylin and Eosin.¹⁰

Photomicrography

The histological results were obtained on photomicrography using digital photograph attached to a research microscope at the Department of Anatomy, School of Basic Medical Sciences, University of Benin, Benin-City, Edo State, Nigeria.

Biochemical Assays

Serum was used to determined urea¹¹, creatinine¹², malonaldehyde (MDA)¹³, catalase(CAT)¹⁴, superoxide dismutase (SOD).¹⁵

Statistical analysis: Renal and antioxidant parameters were evaluated for statistical significance. Data are expressed as the mean \pm SEM. The data were analyzed by analysis of variance (ANOVA) followed by least square difference using the Statistical Package for the Social Sciences (S.P.S.S. 17). The analysed data were represented with tables. The level of significance was set at $p < 0.05$.

RESULT

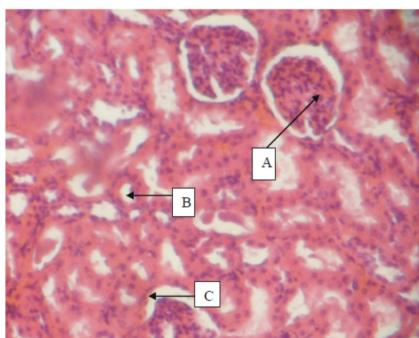


Fig. 1 Control: Rat kidney composed of glomeruli A, tubules B and interstitial space C (H&E x 100)

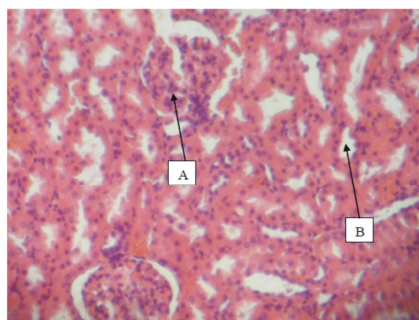


Fig.2: Rat kidney given *Cocos nucifera* water only showing normal glomerulus A and tubules B (H&E x 100)

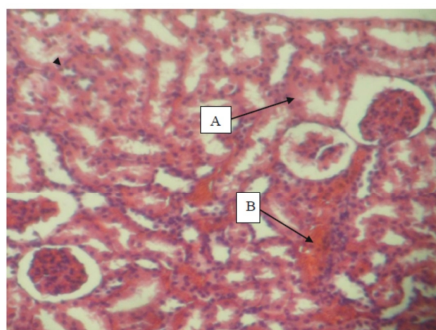


Fig. 3: Rat kidney given Gentamycin only showing focal areas of tubular epithelial cloudy swelling A and mild interstitial congestion B (H&E x 100)

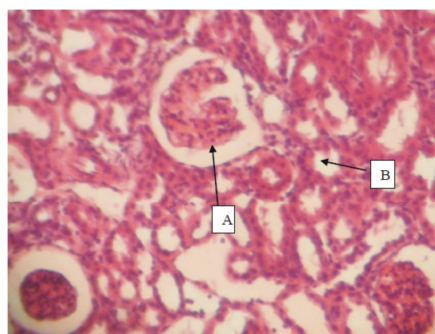


Fig.4: Rat kidney given *Cocos nucifera* water and Gentamycin showing unremarkable renal tubular epithelium A and patent lumen B (H&E x 100)

Biochemical Findings

The mean Urea and Creatinine were both highest in gentamycin treated group (56.67±10.33) and (1.94±0.40) when compared with other groups. The mean SOD was highest in Gentamycin treated rats (92.33 ± 2.34) and lowest in Control rats who received 1ml of sterile water daily (to control for the stress of drug administration). The mean CAT level was also found to be elevated in all treatment

groups and highest in group C (229.17 ± 14.29) when compared to control (171.17 ± 2.23). In addition, the mean MDA was lowest in gentamycin treated group (2.97±0.36) when compared with other group. The comparison of mean Urea, Creatinine, SOD, CAT and MDA levels between *Cocos nucifera* water + Gentamycin treated rats (group D), Gentamycin only treated rats (group C), *Cocos nucifera* water only treated rats (group B) and Control rats were statistically significant (p<0.001 for all comparisons).

Table 2: Renal Function Parameters of the Control Group with Treated Groups

		GROUP A	GROUP B	GROUP C	GROUP D	ANOVA- P VALUE
UREA	Mean(SD)	24.7 (1.60)	24.0(3.10)	56.67(10.33)	24.67(4.13)	<0.001
CREATININE	Mean(SD)	0.80 (0.06)	0.82(0.02)	1.94(0.04)	0.82(0.01)	<0.001

Table 3: Antioxidant Enzymes Parameters of the Control Group with Treated Groups

		GROUP A	GROUP B	GROUP C	GROUP D	ANOVA- P VALUE
SOD	Mean(SD)	57.83(1.47)	60.67(2.07)	92.33(2.34)	63.00(2.10)	<0.001
CAT	Mean (SD)	171.17(2.23)	181(2.00)	229.17(14.29)	183.50(3.89)	<0.001
MDA	Mean (SD)	8.33(0.82)	8.33(0.27)	2.97(0.36)	8.15(0.15)	<0.001

DISCUSSION

Naturally, it is a well known fact that gentamycin causes nephrotoxicity.¹⁶ while *Cocos nucifera* water can act has an antioxidant.¹⁷ It is therefore important to investigate if *Cocos nucifera* water can ameliorate the effect of gentamycin on the kidney. In the present study, there was elevation of both serum urea and creatinine level in gentamycin only group (Table 2) signifying the toxicity nature of gentamycin and also corroborating early work done.¹⁶ The normalization of urea and creatinine level in *Cocos nucifera* water only group and also co-administered group shows the non toxic and ameliorative nature of *Cocos nucifera* water on the kidney. Our results corroborates the findings of other report.¹⁷ Where it was concluded that *Cocos nucifera* water has ability to inhibit the oxidative stress genes therefore help in maintaining normal activity of oxidative enzymes.

The mean superoxide dismutase and catalase were highest while malonaldehyde was lowest in Gentamycin only group (92.33 ± 2.34). These results arises due to the deleterious oxidative stress the gentamycin might had on the kidney tubules by releasing nitric oxide, superoxide and hydrogen peroxide that might have acted on the kidney tubular protein, lipid and carbohydrate thereby leading to cytoarchitectural distortion as evidenced by the biochemical parameters in Table 3.

The above findings is strongly supported by early work done.¹⁸ Morales et al.¹⁸ stated that cytosolic gentamycin act directly and also indirectly by attacking mitochondria, inhibits respiration and therefore reduces ATP production, and generates oxidative stress. Also this oxidative stress occurred mainly in the renal tubular cells.¹⁹ This oxidative stress is interceded by hydroxyl radicals from hydrogen peroxide and also by superoxide anions.^{20,21} The mean superoxide dismutase, catalase and malonaldehyde values were normal in co-administered group, *Cocos nucifera* water only group and Control rats group. This normalcy may arises due to antioxidant effect of *Cocos nucifera* water on biochemical parameter. Our present studies are substantiated by previous reports.¹⁷

The photomicrograph of the kidney in the control showed normal histological features with a detailed cortical parenchyma and the renal corpuscles appearing as dense rounded structures with the glomerulus surrounded by a normal Bowman's space (Figure 1). The group B where only *Cocos nucifera* water was given also

showed normal glomerulus, tubules and interstitial spaces (Figure 2) while gentamycin only group showed a lot of distortion and tubular epithelial cloudy swelling (Figure 3). The co-administered group revealed unremarkable tubular epithelium and patent lumen (Figure 4).

The observed changes in gentamycin only group might be due to the cytotoxic effect of gentamycin on the kidney (Figure 3). Nephrotoxicity caused by aminoglycosides manifests noticeably and possessed typical alteration in lysosomes of proximal tubular cells which are consistent with the buildup of polar lipids.²² These alterations are accompanied by signs of tubular dysfunctions or changes (liberation of brush border and lysosomal enzymes, reduced reabsorption of filtered protein.).¹⁶

Furthermore the group D where both coconut water and gentamycin were given showed unremarkable tubular epithelium and patent lumen (Figure 4). These ameliorative strength may arises due to the anti-oxidant effect of the *Cocos nucifera* water. Our findings are supported by earlier work done.^{23,24} They discovered that *Cocos nucifera* water naturally possesses antioxidant properties.

CONCLUSION

In conclusion, our findings showed that gentamycin administration causes marked histological and biochemical derangement in the kidney, while *Cocos nucifera* water was able to ameliorate this toxic effect due to its antioxidant potentials.

RECOMMENDATIONS


Cocos nucifera water may be recommended as a therapeutic supplement in the treatment of gentamycin toxicity in the kidney.

REFERENCES

1. Lee SM, Pattison ME, Michael UF. Nitrendipine protects against aminoglycoside nephrotoxicity in rats. J. of cardiovascu.Pharmacol.1987; Suppl 1: S65-S69.
2. Reddy KV, Das M, Das SK. Filtration resistances in non-thermal sterilization of green coconut water. J Food Eng. 2005; 69: 381-385.

3. Muanya C. Researchers validate coconut water as nature's energy drink Coco info International,2009; 2004, 2(1): ISBN 0854-5006.
4. Campbell – Falck D, Thomas T, Falck TM, Tutuo N, Clem K. The intravenous use of Coconut water. Am. J. Emerg. Med 2000; 18 (1): 108 – 111.
5. Cumbimuni- Torres KY, Kubota LT. Simultaneous determination of calcium and potassium in coconut water by flow –injection method with tubular potentiometric sensors. J Food Comp Anal.2006; 19: 225-230.
6. Jirovetz L, Buchbauer G, Ngassoum MB. Solid-phase-microextraction-headspace aroma compounds of coconut milk and meat from cameroon. Ernährung Nutr. 2003; 27: 300-303.
7. Aluisio M. da Fonseca; Ayla M.C. Bizerra; Joao Sammy N. de Sousa; Francisco Jose Q. Monte; Marcos C. de Mattos; Geoffrey A. Cordell; Raimundo Braz-Filho; Telma L. G. Lemos. Constituents and antioxidant activity of two varieties of coconut water. Rev. bras. Farmacogn. Vol. 19 no. 1b Joao Pessoa Jan. / Mar. 2009.
8. Nwangwa EK, Aloamaka CP, Igweh JC. Attenuating Effects of *Cocos nucifera* Water on Alcohol-Induced Liver Enzyme Derangement and Hepatopathological Changes. Int. Journal of Modern Biology and Medicine 2012; 1(3): 132-144.
9. Pavle Randjelovic, Slavimir Veljkovic, Ljubinka Jankovic Velickovic, Dusan Sokolovic. Salicylic Acid Attenuates Gentamicin-Induced Nephrotoxicity in Rats. The Scientific World Journal Volume 2012. Article ID 390613.
10. Drury R A B., Wallington EA and Cameron RC. Histological techniques: 4th ed., Oxford university press NY. USA. 1976; 279-280.
11. Patton C and Crouch S : A colorimetric method for the determination of blood urea concentration. J. Anal. Chem., 1977; 49: 464-469.
12. Jaffe M. Quantitative colorimetric determination of creatinine in serum or urine. Zeitschrift fur Physiologische Chemie. 1986; 10: 391-400.
13. Yagi K. Lipid peroxides and human diseases. Chemistry and Physics of Lipids 1987; 2-4.
14. Aebi HE. Catalase. In: Bergmeyer HU, Bergmeyer J, Grabl M, editors. Methods of enzymatic analysis. Vol. 3. Weinheim. Verlag Chemie GmbH; 1993; 273–286.
15. Kakkar P, Das B, Viswanathan PN. A modified spectrophotometric assay of superoxide dismutase. Indian Journal of Biochemistry and Biophysics. 1984; 21(2): 130-132.
16. Gilbert DN. Aminoglycosides.in principles and practice of infectious diseases, Mandell G. L., (Churchill Livingstone, New York, N.Y), 1995; 4th ed. 279-306.
17. Gandhi M, Aggarwal S, Puri S, Singla SK. Prophylactic effect of coconut water on ethylene glycol induced nephrocalcinosis in male wistar rat. Int. braz j urol. Vol. 39 no. 1 Rio de Janeiro Jan. / feb. 2013.
18. Morales AI, Dettaille D, Prieto M, Puente A, Briones E, Arevalo M, Lerveve X, Lopez-Novoa JM, El- MY. Metformin prevents experimental gentamycin-induced nephropathy by mitochondria- dependent pathway. Kidney Int. 2010; 77: 861-869.
19. Karatas Y, Secilimis MA, Karayaylali, Doran F, Buyukafsar K, Singirik E, Saglikler Y, Dikmen A. Effect of tempol (4-hydroxyl tempo) on gentamycin-induced nephrotoxicity in rats. Fundam. Clin. Pharmacol. 2004; 18: 79- 83.
20. Basnakian AG, Kaushal GP, Shah SV, Apoptotic pathways of oxidative damage to renal tubular epithelial cells. Antioxid. Redox Signal. 2002; 4: 915-924.
21. Nakajima T, Hishida A, Kato A, Mechanisms for protective effects of free radical scavengers on gentamicin –mediated nephropathy in rats. Am J. Physio.1994; 266: F425-F431.
22. Begg EJ, Barclay ML. Aminoglycosides 50 years on. Br. J.Clin Pharmacol. 1995; 39(6): 597- 603.
23. Leong LP, Shui G. An investigation of antioxidant capacity of fruits in Singapore markets. Food Chem 2002; 76: 69-75.
24. Skrede G, Larsen VB, Aaby K, Jorgensen AS, Birkeland SE. Antioxidative properties of commercial fruit preparations and stability of bilberry and black currant extracts in milk products. J Food Sci 2004; 69: 351-356.

Source of support: Nil, Conflict of interest: None Declared

<p>QUICK RESPONSE CODE</p> 	<p>ISSN (Online) : 2277 –4572</p> <p>Website http://www.jpsionline.com </p>
-----------------------------------------------------------------------------------------------------------------------	--------------------------------------------------------------------------------------------------------------------------

How to cite this article:

Ehimigbai, Agbonluai Richard O., Anunobi, Arinze Albert. Ameliorative effect of *Cocos nucifera* (coconut) water on gentamycin induced renal toxicity in adult wistar rat. J Pharm Sci Innov. 2015;4(3):168-171 <http://dx.doi.org/10.7897/2277-4572.04337>

Disclaimer: JPSI is solely owned by Moksha Publishing House - A non-profit publishing house, dedicated to publish quality research, while every effort has been taken to verify the accuracy of the content published in our Journal. JPSI cannot accept any responsibility or liability for the site content and articles published. The views expressed in articles by our contributing authors are not necessarily those of JPSI editor or editorial board members.