



## FISSURE IN ANO: A CLINICAL APPROACH

Ashish Soni\*

Ayurvedic Medical Officer, Distt. Pali, Government of Rajasthan, India

\*Corresponding Author Email: dr.ashishsoni84@gmail.com

DOI: 10.7897/2277-4572.0411

Received on: 15/12/14 Revised on: 08/01/15 Accepted on: 04/02/15

## ABSTRACT

Anorectal disorders such as fissure in ano, hemorrhoid, sinus, fistula in ano are direct link with our life style and bowel habit. Sedentary lifestyle, spicy and junk food, prolong sitting, smoking, alcohol are predisposing factors of altered bowel habit which is major cause of these notorious diseases. Fissure in ano is a split at muco-cutaneous junction in anal canal. It causes intense pain during defecation with passage of small amount of blood. Primary fissure can be acute or chronic while secondary are due to underlying diseases. Acute fissure usually respond to conservative treatment, if not then convert into chronic fissure associated with tag which is treated with surgical intervention. Fissure in ano is described as parikartika in Ayurvedic literatures by complication of virechan (purgation therapy). It is due to alleviation of vata and pitta dosha which causes severe pain with burning sensation. Avagaha sweda (sitz bath), high fiber diet isabgol, local application of jatyadi oil, guggulu preparation are such measures prove highly efficacious in management of fissures. Bilwadi churna, kutaj, takra are effective in colitis or IBS which causes secondary fissure. These Ayurvedic medicaments can prevent acute fissure to convert in chronic one hence probability of surgery can be reduced to a great extent.

**Keywords:** Fissure, parikartika, virechana, isabgol, jatyadi, bilwadi.

## INTRODUCTION

A disturb lifestyle pattern has very superior role to cause various types of anorectal disorders. Lack of adequate physical activity, fast food, unhealthy diet, smoking, alcohol, tobacco, prolong sitting job, improper intake of water make gastrointestinal tract (GIT) disturbance which result irregular bowel habit. Altered bowel habit is major factor to cause hemorrhoids, fissure in ano, abscess, sinuses, fistula in ano and other types of anorectal disorders. Acharya Charaka also notified that arsha (hemorrhoids), atisara (various form of diarrhea) and grahani (irritable bowel syndrome) diseases are concomitant with each other.<sup>1</sup> Fissure in ano is an oval, ulcer like, longitudinal tear at the muco-cutaneous junction extending from the anal verge towards the dentate line. It was first recognized as a disease in 1934.<sup>2</sup> The usual clinical presentation is of intense anal pain made worse by attempted defecation accompanied with the passage of small amounts of blood. Anal fissure is most common cause of severe anal pain and bleeding per anus in adult and children also. It affects more than 10 % of patient attending proctology clinic<sup>3</sup> and the incidence is growing high day by day. Primary fissure can be classified in acute and chronic condition. Acute fissures have the appearance of a simple tear in the anoderm cause intense pain and may resolve with conservative treatment, whereas chronic fissures defined by symptoms lasting more than 8 to 12 weeks, are further characterized by edema and fibrosis. Typical inflammatory manifestations of chronic fissures include a sentinel skin tag at the distal fissure margin and a hypertrophied anal papilla proximal to the fissure in the anal canal. Secondary fissures are due to underlying diseases such as colitis, crohn's disease, tuberculosis, previous anal operation, AIDS, syphilis etc. have different presentations and need specific line of management. In Ayurvedic literature fissure in ano is not defined as a separate disease. This disease is described under heading of parikartika by all acharyas. According to charaka it is a complication of virechana (purgation).<sup>4</sup> Sushruta also mentioned parikartika as complication of, virechana and due to mal position of vastinetra during vastichikitsa. Its treatment in form of both local and general is well defined by Sushruta.<sup>5-8</sup> Parikartika is occur by influence of vata and pitta dosha, vata causes pain like cutting with a sharpe instrument (i.e. scissors) and pitta causes burning sensation

along with inflammation. In the same way it is said that parikartika is a type of wound occurs due to trauma by vishtambhi mala (hard stool) in guda marga (anal canal). Various types of medicaments are in Ayurveda such as ushna avagaha sweda (hot sitz bath), jatyadi or other healing oil preparations, guggulu preparations, natural fiber isabgol etc.

## Etiology

Alteration of bowel habit is said to be a common predisposing factor, it is suggested that the passage of hard faeces results in direct trauma to the posterior aspect of anal canal<sup>9</sup> this causes crack at muco-cutaneous junction which is rich in somatic nerve supply results pain. Once an anal fissure develops, there is usually excessive activity of the internal anal sphincter<sup>10</sup> and high resting anal pressures which perpetuate the condition.<sup>11</sup> Such sphincter spasm is responsible for a vicious circle of anal pain, fear of defecation and passage of hard stools which stimulates further internal sphincter activity. Recent research has shown the blood flow to the posterior midline of the anus is potentially deficient, being supplied by end arteries (mean arteriolar blood pressure 85 mmHg), which passes through the internal anal sphincter before reaching the posterior commissure.<sup>12</sup> As the maximum resting anal pressure (MRAP) is usually greater than 90 mmHg in patients with fissures<sup>13</sup>, such hypertonia will compress these end arteries and cause ischemia of the posterior commissure. This is the foremost cause that fissures occur more frequently in posterior midline region of anal canal. Usually acute fissure respond to conservative treatment but sometimes symptoms may persist and fissure converts in chronic variety. The fissure is described as chronic if it fulfils following criteria<sup>14</sup>:

- If it is not responding to conservative treatment.
- Presence of external skin tag is noticed.
- Presence of fibrous anal polyp.
- In-duration is indicated at the edges of fissure.
- If there is exposure of the fibers of the internal sphincter at the floor of the fissure.
- A bridged fissure with underlying fistula.

Constipation/ altered bowel habit → hard stool/ frequent stool → trauma to muco-cutaneous junction of anal canal → tear or acute fissure → either heal or convert into chronic → stasis of fecal matter or infectious agent in chronic wound → results infection of the crypt of anal canal → infection travels through anal gland to external environment → abscess → burst → fistula.

### Clinical features and diagnosis of fissure in ano

The principle symptoms in adults are anal pain, bright red bleeding, perianal swelling and occasionally mucous discharge. The pain is acute and is felt in the anal canal during and after defecation. There may be a sensation of tearing during defecation. A dull ache is usually experienced for 3-4 hours after defecation. Constipation soon complicates the clinical picture and aggravates symptoms. Pain may become chronic and intermittent. Bleeding is only small in amount, is bright red in color. Profuse blood loss is rare. Swelling and discharge are characteristic of chronic fissure, which may be complicated by pruritis ani and perianal excoriation. Discharge may indicate an intersphincteric abscess or a fissure-fistula.

### Examination

In most patients it is possible to make a diagnosis of anal fissure by inspection alone. The patient is usually anxious and may be in pain also patients are naturally fearful of having a rectal examination and the perianal skin is usually puckered by spasm of the internal and external anal sphincters and tightly held buttocks.

### Inspection

Despite excessive sphincter activity, it is usually possible to notice a skin tag along with a small amount of blood or discharge on the perineum. Gentle traction on the lateral margins of the perineum nearly always reveals a fissure if one is present below the dentate line. Sometime perianal dermatitis (fungal dermatitis) also present near anal verge which causes itching to the patient. In this condition it is necessary to treat dermatitis along with fissure.

### Palpation

This is performed only after inspection to go through any associate pathology in anal canal. Digital rectal examination (DRE) is to be done by introducing properly lubricated index finger and thumb remains outside to palpate pathology around anal verge. Intense spasm of the sphincters and an irregular, painful depression near the anal margin are usually prominent features of acute fissure. In chronic fissure a fissure bed with indurated edges is present which sometime associates with hypertrophied anal papilla. Subcutaneous abscess, submucosal abscess and intersphincteric abscess associated with chronic fissure are also noticed sometimes by digital rectal examination.

### Proctoscopy

It is usually note done in case of fissure in ano, if hemorrhoid or other pathology present it can be done in local anesthesia.

### Sigmoidoscopy

This is necessary in case of secondary fissure to identify the primary pathology. It is done under general anesthesia to diagnose distal proctitis, colitis, crohn's disease, tuberculosis, adenomatous polyps which can cause secondary fissure.

### Fissure associated with other diseases

A small proportion of fissures are secondary to other pathology. Anal fissures in Crohn's disease are usually painless.<sup>15</sup> Sepsis around the fissure is common and there is often a prominent skin

tag. The fissure is in form of cavitating ulcer may be situated laterally and there may be more than one. Associated fistula, abscess and stenosis are frequent. Tuberculous fissures rarely heal with conventional therapy and frequently progress to form an ulcer with undermined edges. Destruction of sphincter muscle may follow, resulting in multiple anal fistulas. In syphilitic fissure primary chancre may resemble a fissure but it is usually painless and rapidly becomes indurated, with associated inguinal lymphadenopathy. There are often two fissures that lie opposite each other around the circumference of the anal margin. In this condition diagnosis is confirmed by sample of discharge from anal canal.

### Management

Up to 70 % of acute fissure resolve with conservative medicine, if not they progress to form a chronic fissure. However, Ayurvedic preparations are used in primary stage of disease the chance to progression in chronic one can be minimized. The main aim of treatment is to relive spasm of sphincter, cleaning and healing of fissure wound, soothing of anal canal, minimize the pain. It is my personal experience that avgaha sweda (hot fomentation sitz bath), dietary fibers like isabgol (psyllium husk), oil preparation made of various medicinal plant, guggulu preparation can treat acute fissures almost more than 90 % of patients. There are so many topical applicant are available such as topical anesthetic agent, steroids, nitrate preparation, topical calcium channel blocker, injection of botulinum toxin, sclerotherapy using sodium tetradecyl sulphate preparations in the modern medical science but all have certain limitations. Various surgical procedures such as anal dilatation, fissurectomy, fissurectomy with skin grafting, open sphincterotomy, closed lateral subcutaneous sphincterotomy, sphincterotomy with cryotherapy, sphincterotomy with radiofrequency surgery are used to treat in various stage of chronic fissure and sentinel tag. But impairment of continence, fistula or abscess formation, bleeding, wound healing are the more or less complication with these surgical procedure. To avoid these complications Ayurvedic medicament can be use as:

### Avgaha sweda (hot fomentation-sitz bath)

Sitting in the warm/hot water tub after each bowel movement soothes pain and relaxes spasm of internal sphincter for some time. It also helps in cleaning of fissure wound. Sitz bath is highly effective in treatment of fissure. It is done for 10 to 15 minutes.

### High Fiber Diet

Isabgol (psyllium husk) are portions of the seeds of the plant *Plantago ovata*. These are hygroscopic, which allows them to expand and become mucilaginous. These fibers are a complex carbohydrate, which binds with water in the colon creating larger, softer, stool. Larger, softer, stools stretch and relax the sphincter muscles helping the blood to flow and it also require little pressure to pass. Psyllium fiber is widely used as a fiber supplement for the treatment of constipation and has in clinical trials reported significantly increased levels of stool moisture, as well as wet and dry stool weight in healthy subjects.<sup>16-18</sup> It has been reported that each gram of psyllium fiber increases stool weight an average of 5.9-6.1 g.<sup>18</sup> Psyllium has also been shown to slow down the gastric emptying time and colon transit, this being of benefit for individuals with diarrhea and fecal incontinence from liquid stools.<sup>19-20</sup> So this Ayurvedic preparation is very safe, cheap and highly efficacious in altered bowel habit or in IBS also.

### Jatyadi ghee/oil

It is mentioned in Bhaisajya ratnawali in the reference of vrana (wound).<sup>21-22</sup> It is prepared with chameli patra (leaves of *Jasminum officinale*), nimba patra (leaves of *Azadirachta indica*), haridra (*Curcuma longa*), daruharidra (*Berberis aristata*), mulethi (*Glycyrrhiza glabra*), kutaki (*Picrorhiza kurroa*) bee wax and other

plants. Local application of jatyadi oil/ghee show tremendous results by;

- It forms a protecting layer over fissure wound.
- It soothes anal canal so relive pain by relaxing sphincter tone.
- It cleans wound as well as very good healing property.

### Guggulu (*Commiphera mukul*) preparation

Triphala guggulu, kaishor guggulu, shigru guggulu, lakshadi guggulu have been shown very good results in management of

various anorectal disorder. Triphala guggulu is used in unhealthy and large wound. It also relive in constipation. Kaishor guggulu is effective when there is associate dermatitis, itching and excessive burning condition. Shigru guggulu is given when there is much inflammation and pain. Lakshadi guggulu is effective in associate bleeding pile mass. It is my personal experience for patients.

In secondary fissure where colitis is primary disorder bilwa (*Eagle marmelos*), kutaj (*Holarrhena antidysentrica*), takra (butter milk) can be the first line of treatment.

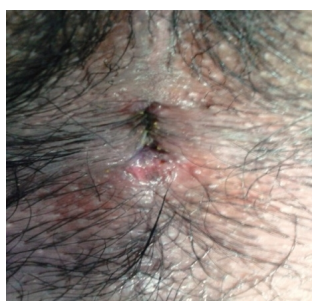

Figure 1: Acute fissure in ano

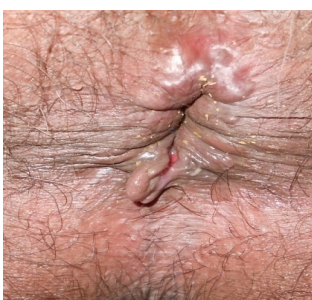

Figure 3: Chronic fissure with tag and external 11'o' clock hemorrhoid

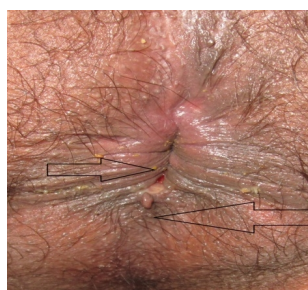

Figure 2: Chronic fissure with small tag

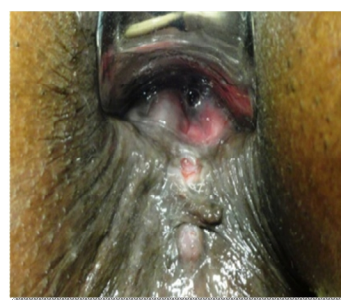

Figure 4: Chronic fissure with tag and fistulous opening

### CONCLUSION

Ayurvedic preparations are all effective that may obviate the need for anesthesia and surgery in many of patients. These preparations can cure fissure and regulate bowel up to 90 % cases of acute fissure. These could always be offered to the patients who are not willing for operative procedure such as cardiac patients or patients with diabetes, AIDS, hepatitis B, where healing is difficult after operation. There are many drugs highly effective in chronic colitis and IBS as these are chief cause of secondary fissures. Jatyadi oil and guggul preparation can also be used after surgical procedure to faster healing.

### REFERENCES


1. Kashinath Shashtri, Gorakhnath Chaturvedi, Charaka Samhita of Charak and Dradhbala, Chikitsa Sthan, Arsha Chikitsa, Chapter 14/244, Chaukhambha Bharti Academy, Varanasi, Reprint; 2006. p. 448.
2. Dziki A, Trzcinski R, Langner E, Wronski W. New approaches to the treatment of anal fissure. Acta Chir Iugosl 2002; 49: 73-75. <http://dx.doi.org/10.2298/ACI0202073D>
3. Pescatori M. Soiling and recurrence after internal sphincterotomy for anal fissure. Dis Colon Rectum 1999; 42: 687-688. <http://dx.doi.org/10.1007/BF02234154>
4. Kashinath Shashtri, Gorakhnath Chaturvedi, Charaka Samhita of Charak and Dradhbala, Siddhi Sthan, Vaman Virechana

vyapadsiddh, Chapter 6/29, Chaukhambha Bharti Academy, Varanasi, Reprint; 2006. p. 1023 and Siddhi Sthan, Chapter 6/61-67, Chaukhambha Bharti Academy, Varanasi, Reprint; 2006. p. 1028.

5. Kaviraja Ambikadutta Shastri, Sushruta Samhita of Maharishi Sushruta edited with Ayurveda Tattva Sandipika, Chikitsa Sthan, Vaman Virechana vyapadchikitsa, Chapter 34/3, Chaukhamba Sanskrit Sansthan, Varanasi, Reprint; 2007. p. 147.
6. Kaviraja Ambikadutta Shastri, Sushruta Samhita of Maharishi Sushruta edited with Ayurveda Tattva Sandipika, Chikitsa Sthan, Vaman Virechana vyapadchikitsa, Chapter 34/16, Chaukhamba Sanskrit Sansthan, Varanasi, Reprint; 2007. p. 151.
7. Kaviraja Ambikadutta Shastri, Sushruta Samhita of Maharishi Sushruta edited with Ayurveda Tattva Sandipika, Chikitsa Sthan, Netravasti pramanpravibhag, Chapter 35/32, Chaukhamba Sanskrit Sansthan, Varanasi, Reprint; 2007. p. 155.
8. Kaviraja Ambikadutta Shastri, Sushruta Samhita of Maharishi Sushruta edited with Ayurveda Tattva Sandipika, Chikitsa Sthan, Netravasti vyapadchikitsa, Chapter 36/37-38, Chaukhamba Sanskrit Sansthan, Varanasi, Reprint; 2007. p. 158.

9. Lund JN and Scholefield JH. Etiology and treatment of anal fissure. *Br J Surg* 1996; 83: 1335-1344. <http://dx.doi.org/10.1002/bjs.1800831006>
10. Sumfest JM, Brown AC and Rozwadowski JV. Histopathology of the internal anal sphincter in chronic anal fissure. *Dis Colon Rectum* 1989; 32: 680-683. <http://dx.doi.org/10.1007/BF02555773>
11. Mc Namara MJ, Percy JP and Fielding IR. A manometric study of anal fissure treated by subcutaneous lateral internal sphincterotomy. *Ann Surg* 1990; 211: 235-237. <http://dx.doi.org/10.1097/0000658-199002000-00017>
12. Mc Callion K, Gardiner KR. Progress in the understanding and treatment of chronic anal fissure. *Postgrad Med J* 2001; 77: 753-758. <http://dx.doi.org/10.1136/pmj.77.914.753>
13. Klosterhalfen B, Vogel P, Rixen H, Mittermayer C. Topography of the inferior rectal artery: a possible cause of chronic, primary anal fissure. *Dis Colon Rectum* 1989; 32: 43-52. <http://dx.doi.org/10.1007/BF02554725>
14. The standard task force American society of Colon and Rectal surgeons. Practice parameters for the management of anal fissure. *Dis Colon Rectum* 1992; 32: 206-208.
15. Sweeney JL, Ritchie JK and Nicholls RJ. Anal fissure in Crohn's disease. *Br J Surg* 1988; 75: 56-57. <http://dx.doi.org/10.1002/bjs.1800750120>
16. Marteau P, Flourie B, Cherbut C, Correze JL, Pellier P, Seylaz J and Rambaud JC Digestibility and bulking effect of ispaghula husks in healthy humans. *Gut* 1994; 35: 1747-1752. <http://dx.doi.org/10.1136/gut.35.12.1747>
17. Levitt MD, Furne J and Olsson S. The relation of passage of gas an abdominal bloating to colonic gas production. *Annals of internal medicine* 1996; 124: 422-424. <http://dx.doi.org/10.7326/0003-4819-124-4-199602150-00006>
18. Marlett JA, Kajs TM and Fischer MH. An unfermented gel component of psyllium seed husk promotes laxation as a lubricant in humans. *American Journal of Clinical Nutrition* 2000; 72: 784-789.
19. Washington N, Harris M, Mussellwhite A and Spiller RC. Moderation of lactulose-induced diarrhoea by psyllium: effects on motility and fermentation. *The American journal of clinical nutrition* 1998; 67: 317-321.
20. Bliss DZ, Jung HJ, Savik K, Lowry A, Le Moine M, Jensen L, Werner C and Schaffer K. Supplementation with dietary fiber improves fecal incontinence. *Nursing Research* 2001; 50: 203-213. <http://dx.doi.org/10.1097/00006199-200107000-00004>
21. Siddhi Nandan Mishra, Bhaisajya Ratnavali of Kaviraj Govind Das Sen edited with Siddhiprada Hindi commentary, Vranashotha adhikar, Chapter47/51, Chaukhamba Surbharati Prakashan, Varanasi, reprint; 2012. p. 824.
22. Siddhi Nandan Mishra, Bhaisajya Ratnavali of Kaviraj Govind Das Sen edited with Siddhiprada Hindi commentary, Vranashotha adhikar, Chapter47/62-66, Chaukhamba Surbharati Prakashan, Varanasi, reprint; 2012. p. 825-826.

Source of support: Nil, Conflict of interest: None Declared

<p><b>QUICK RESPONSE CODE</b></p> 	<p>ISSN (Online) : 2277 –4572</p> <hr/> <p>Website  <a href="http://www.jpsionline.com">http://www.jpsionline.com</a> </p>
---	--

**How to cite this article:**

Ashish Soni. Fissure in ano: A clinical approach. *J Pharm Sci Innov.* 2015;4(1):1-4 <http://dx.doi.org/10.7897/2277-4572.0411>