



HEPATOPROTECTIVE ACTIVITY OF *EUPHORBIA HIRTA* LINN. PLANT AGAINST CARBON TETRACHLORIDE -INDUCED HEPATIC INJURY IN RATS

Dubey Subodh^{1*}, Mehta S. C.²

¹IPS College of Pharmacy, Shivpuri link road, Gwalior, M.P., India

²G. R. Medical College Gwalior, M.P., India

*Email: subodh.dubey39@gmail.com

Received on: 15/05/12 Revised on: 20/05/12 Accepted on: 06/06/12

ABSTRACT

Ethanol extract of *Euphorbia hirta* Linn was prepared and tested for its hepatoprotective effect against CCl₄-induced hepatitis in rats. Alteration in the levels of biochemical markers of hepatic damage like SGPT, SGOT, ALP, bilirubin, were tested in both treated and untreated groups. Carbon tetra chloride (2 ml/kg) has enhanced the SGPT, SGOT, ALP and bilirubin. Treatment with Ethanol extract of *Euphorbia hirta* Linn (100 mg/kg and 300 mg/kg) has brought back the altered levels of biochemical markers to the near normal levels in the dose dependent manner.

KEYWORDS: *Euphorbia hirta* Linn, CCl₄, Hepatoprotective, Silymarin

INTRODUCTION

Alternative Systems of medicine Viz. Ayurveda, Siddha, and Traditional Chinese medicine have become more popular in recent years. Medicinal herbs and extracts prepared from them are widely used in the treatment of liver disease like hepatitis, cirrhosis and loss of appetite. Liver diseases are of the serious health problems due to absence of reliable liver protective drugs in allopathic medical practices¹.

Euphorbia hirta Linn (Family: Euphorbiaceae) commonly known as Dudhi, is an herb used in Indian system of medicine in disease of children like worm infestation, bowel complaints and cough. The decoction of the plant has been reported to useful in the treatment of bronchial asthma. It has also been used for liver ailments in the absence of reliable liver protective drugs in modern medicine; there are numbers of medicinal preparations in the Ayurvedic system of Indian medicine recommended for the treatment of Liver disorders. It is found commonly as wild plant at road sides & in gardens throughout India. It is an annual herb about 15-20 cm high erect or ascending, often branched from the base & sometimes with a woody base, hispid with long yellowish crisped hairs. Stem is usually terete. The leaves are opposite, 1.0 - 4.0 cm x 0.5 - 1.5 cm, obliquely oblong lanceolate, acute, toothed or serrulate, Inflorescence is axillary cyme peduncled and pubescent fruits are depressed globose & keeled. The seeds are reddish brown, 0.08 cm long & ovoid - trigonous. Flowering & fruiting is almost throughout the year².

MATERIAL AND METHODS

Collection and Identification of Drug

The plant of *Euphorbia hirta* Linn (Dudhi) was collected (in the month of July and August) from surrounding field of IPS college Gwalior. The whole plant were dried in shade, and used for extraction. The plant was positively identified and confirmed by the Taxonomist, Dept. of Ayush, Gwalior (M.P.). The voucher specimen (Ref No: 326) of the plant material has been deposited in the Department of Ayush, Gwalior.

Preparation of Extract

The drug was extracted with ethanol in Soxhlet apparatus, the extraction was completed in 25 cycles. The extract was dried and stored in desiccator.

Animals

Healthy adult Male Wistar rats weighing about 200-250g were used for the study. They were housed in groups in polypropylene cages, maintained under standard conditions (12:12h light: dark cycle; 27±3°C; 40–60% humidity) and maintained with free access to standard rat pellet diet (Amrut laboratory animal feed, manufactured by Navmaharashtra chakan oil mills Ltd, Pune) and water *ad libitum*.

The experiments were carried out in accordance with guidelines described by the Institutional Animal Ethics Committee of the Institute (Proposal No.1039/ac/07/CPCSEA)

Acute toxicity Studies

Overnight fasted Albino Wistar rats were subjected to acute toxicity studies to determine the safe dose by acute toxic class method of oral toxicity as per OECD 423 guidelines³. The rats were observed continuously for 2h for behavioral, neurological and autonomic profiles and, after a period of 24, 72 h, and thereafter up to 14 days for any lethality, moribund state or death.

Experimental Induction of Hepatotoxicity

Hepatotoxicity was induced in Albino Wistar rats (150-200g) by intra-peritoneal (i.p.) administration of carbon tetrachloride (1:1 CCl₄: Liquid paraffin in the dose of 2ml/kg) for two continuous days. After 24 hours of last dose of CCl₄, blood was withdrawn from retro-orbital plexus. Serum was separated and analyzed for the various biochemical markers of hepatotoxicity and hepatic damage.

Assessment of hepatoprotective activity

Animal were divided into five groups each having six animals (n =6) Group A was kept as normal, animals of group B (Control) were given intra peritoneal dose of toxin solution 2ml/kg body weight. Animals of group C (stand. drug) were given oral dose of stand. Drug (Silymarin) at the dose of 200 mg / kg body weight. All the test samples (Group D and E) were administered orally to the animals at the dose of 100, 300 mg/ kg body weight respectively.

After one week animal were sacrificed by anaesthetizing them with anaesthetic ether. Blood was withdrawn from retro-orbital plexus and transferred into small vials. It was left undisturbed to separate the serum for estimation of serum parameters. Before that liver was separated and washed with

ringer solution, soaked in filter paper and then transferred into 10 % formalin solution

Histopathological observation

Liver tissue collected were used for the preparation of histopathological slides by using microtome and were suitably stained and observed under microscope for architectural changes seen during CCl₄ challenge in ethanolic extract of *Euphorbia hirta* Linn treated and control groups.

Statistical Analysis

The data were analyzed with one way ANOVA followed by Dunnetts multiple comparison test. P< 0.05 was considered significant in all the cases.

RESULTS

Effect of ethanolic extract of *Euphorbia hirta* Linn on CCl₄ induced liver damage in rats with reference to biochemical changes in serum are shown in Table 1. At the end of the 5th day treatment, blood sample of CCl₄ treated control animals showed significant increase in the level of SGPT, SGOT, ALP, compare to normal control. Treatment with *Euphorbia hirta* Linn extract at 100 and 300 mg/kg showed marked decreased of SGPT, SGOT, ALP, as compared to the CCl₄ treated group. The maximum protection was shown by ethanolic extract at the dose of 300 mg/kg body weight (Table 1). Bilirubin levels are shown in Table 1. The rats exposed to CCl₄ showed significant increased levels of bilirubin as compare to control. Treatment with *Euphorbia hirta* Linn extract showed significant (P < 0.01) decreased level of bilirubin to the near normal which is comparable to the values registered in the standard drug treated (Silymarin) group of animals, indicating the protection of hepatic cells.

The liver cells of group A exhibits normal architecture of hepatocytes without any sign of necrosis or degeneration (Fig.1). The group B animals liver showed cellular degeneration, hydropic change more around the central veins, fatty changes, wide spread cloudy swelling and hepatocellular necrosis and steatosis. The normal architecture of liver is completely damaged (Fig. 2). The liver cells of group C exhibit normal hepatocytes with central vein (Fig. 3).

The liver cells of group D were radially arranged. The vaculation is present but is very much similar to that of normal. The hepatic cells are mostly normal but few vacuoles and some damaged cells, but the extent of the area of necrotic cells located in this region was considerably reduced. There seems to be an appreciable recovery (Fig. 4).

The group E exhibits Nucleuses are not very clear as in normal hepatocytes but as compared to the CCl₄ damaged ones the numbers of hepatocytes with normal nucleus are much more. But the extent of the area of necrotic cells located in this region was considerably highly reduced and improved histology of the liver. There seems to be a strong hepatoprotection and recovery (Fig. 5).

DISCUSSION

Flavonoids are low molecular weight compounds present in all higher plants. To date, more than 5000 structurally distinct flavonoids have been described. The diversity in their chemical structure confers them a wide range of biological activities. In plants, their function seems to be linked to protection against ultraviolet radiation, microbial invasion and both insect and mammalian herbivores. Their actions in humans have been the subject of extensive research and they have been described to possess numerous biological activities

such as antioxidant, anti-inflammatory, oestrogenic, cytotoxic antitumoral, antiviral⁴ and CNS depressant. The most relevant clinical data comes from their use in the treatment of bone loss, vascular diseases and cancer⁵⁻⁷.

The hepatotoxicity induced by CCl₄ is due to its metabolite CCl₃, a free radical that binds to lipoprotein and leads to peroxidation of lipids of endoplasmic reticulum⁸. The ability of a hepatoprotective drug to reduce the injurious effects or to preserve the normal hepatic physiological mechanisms, which have been disturbed by a hepatotoxin, is the index of its protective effects. The lowering of enzymes level are definite indication of hepatoprotective action of the drug. The present investigation also revealed that the given dose of CCl₄ (2 ml/kg b.w.) produced significant elevation in SGPT, SGOT, ALP, Serum Bilirubin indicating all impaired liver function and these parameters have been reported to sensitive indicator of liver injury⁹. Hepatotoxic action of CCl₄ begins with changes in endoplasmic reticulum which result in loss of metabolic enzymes located in the intra cellular structure¹⁰. The ethanolic extract of *E. hirta* Linn when administered orally to rats showed a significant dose dependent hepatoprotective activity at 100 and 300 mg/kg.

The histopathological studies are the evidence of efficacy of drug as protectant. Simultaneous treatment of ethanolic extract with CCl₄ exhibits less damage to the hepatic cells as compared to the rats treated with CCl₄ alone. Liver showed cellular degeneration, hydropic change more around the central veins, fatty change, wide spread cloudy swelling and hepatocellular necrosis and steatosis. The normal architecture of liver is completely damaged. The sections of the liver treated with ethanolic extract of *E. hirta* Linn and CCl₄ reveals better hepatoprotective activity, as compared to the CCl₄ damaged ones the numbers of hepatocytes with normal nucleus are much more. But the extent of the area of necrotic cells located in this region was considerably highly reduced and improved histology of the liver. The results of histopathological study also support the results of biochemical parameters.

REFERENCES

1. Rose and Wilson, Anatomy and physiology in Health and Illness published by Churchill Livingstone, 9th edition, 2001; pp. 281 – 338.
2. Nadkarni KM, Materia Medica published by popular prakashan, edition 1st, 1976; pp. 526 – 527.
3. OECD/OCDE, OECD Guidelines for the testing of chemicals, revised draft guidelines 423: Acute Oral toxicity- Acute toxic class method, revised document, CPCSEA, Ministry of Social Justice and Empowerment, Govt. of India; 2000.
4. Harborne JB, Phytochemical methods, published by Chapman and hall Ltd, edition 1st, 1973.
5. Messina, M., Ho, S., Alekel, D.L. Skeletal benefits of soy isoflavones: areview of the clinical trial and epidemiologic data. Curr. Opin. Clin. Nutr. Metab. Care, 2004; 7:649–658.
6. Katsenis, K., Micronized purified flavonoid fraction (MPFF): a review of its pharmacological effects, therapeutic efficacy and benefits in the management of chronic venous insufficiency. Curr. Vasc. Pharmacol, 2005; (3), 1–9.
7. Van Veldhuizen, P.J., Faulkner, J.R., Lara Jr., P.N., Gumerlock, P.H., Goodwin, J.W., Dakhil, S.R., Gross, H.M., Flanagan, R.C., Crawford, E.D., Southwest Oncology Group, "A phase II study of flavopiridol in patients with advanced renal cell carcinoma: results of Southwest Oncology Group Trial 0109. Cancer Chemother". Pharmacol. 2005; 56:39–45.
8. Recknagel R, Carbontetrachloride hepatotoxicity, Pharmacol Rev, 1967; 19:145-196.
9. Molander DW, Wroblewski F, La Due JS, Transaminase compared with cholinesterase and alkaline phosphatase an index of hepatocellular integrity. Clinical Research Proceedings, 1955; 3:20-24.

10. Conney AH, Burns JJ). The stimulatory effects of foreign compounds on ascorbic acid biosynthesis and on drug metabolizing enzymes, Nature, 1959; 184: 363-364.

Table 1 - Estimation of biochemical parameters

S No.	SGOT U/L	SGPT U/L	S.B. MG/DL	A.P. U/L
GROUP A (Normal)	24.8± 3.55	26.6±3.46	0.8± 0.04	85.4±8.39
GROUP B (Toxic)	150.4±10.61*	400.4±17.27*	5.4±0.03*	400±13.11*
GROUP C (Standard Drug)	78.6±.32 [#]	390±17.38 [#]	0.8± 0.02 [#]	250±15.37 [#]
GROUP D (EtOH Extr.100mg/kg)	98±8.32 [#]	269±11.24 [#]	1.0±0.01 [#]	344±12.46 [#]
GROUP E (EtOH Extr. 300mg/kg)	84.5±8.32 [#]	210±11.24 [#]	1.4±0.02 [#]	290±12.46 [#]

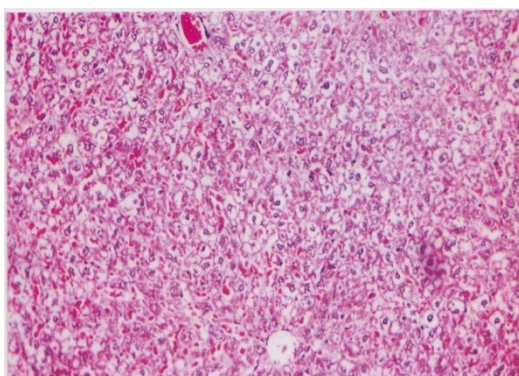


Fig. -1 Photomicrograph of liver section from Group A rats showing normal architecture of hepatocytes

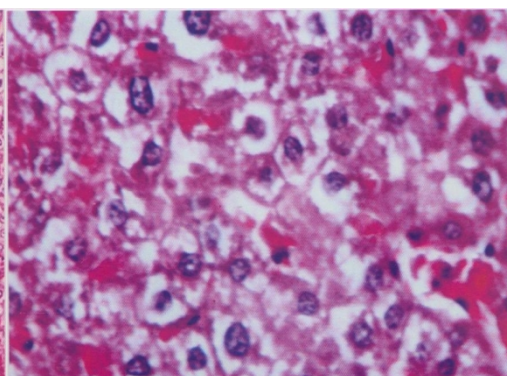


Fig. -2 Photomicrograph of liver section from Group B normal architecture of liver is completely damaged

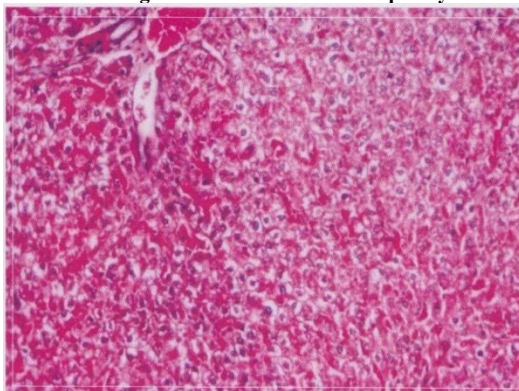


Fig. -3 Photomicrograph of liver section from Group C rats showing normal hepatocytes with central vein

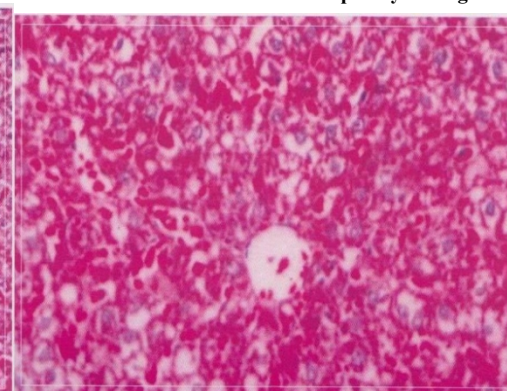


Fig. -4 Photomicrograph of liver section from Group D vacuolation is present but is very much similar to normal

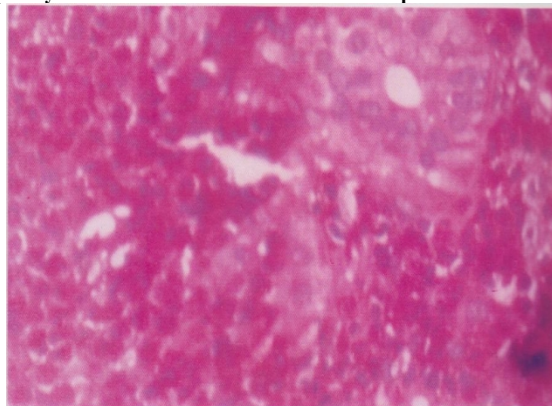


Fig. -5 Photomicrograph of liver section from Group E Nucleuses are not very clear as in normal hepatocytes